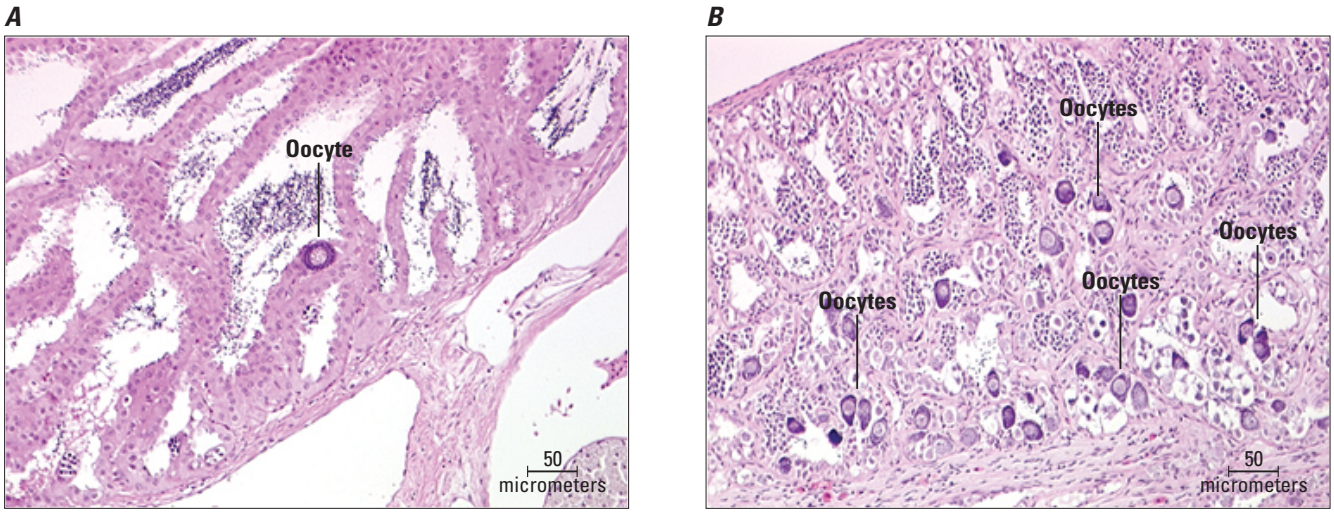

Figure 1. Microscopic appearance of smallmouth bass testes containing *(A)* a single oocyte (severity rating 1); and *(B)* multiple oocytes, commonly in clusters (severity rating 4) (modified from Blazer and others, 2007).