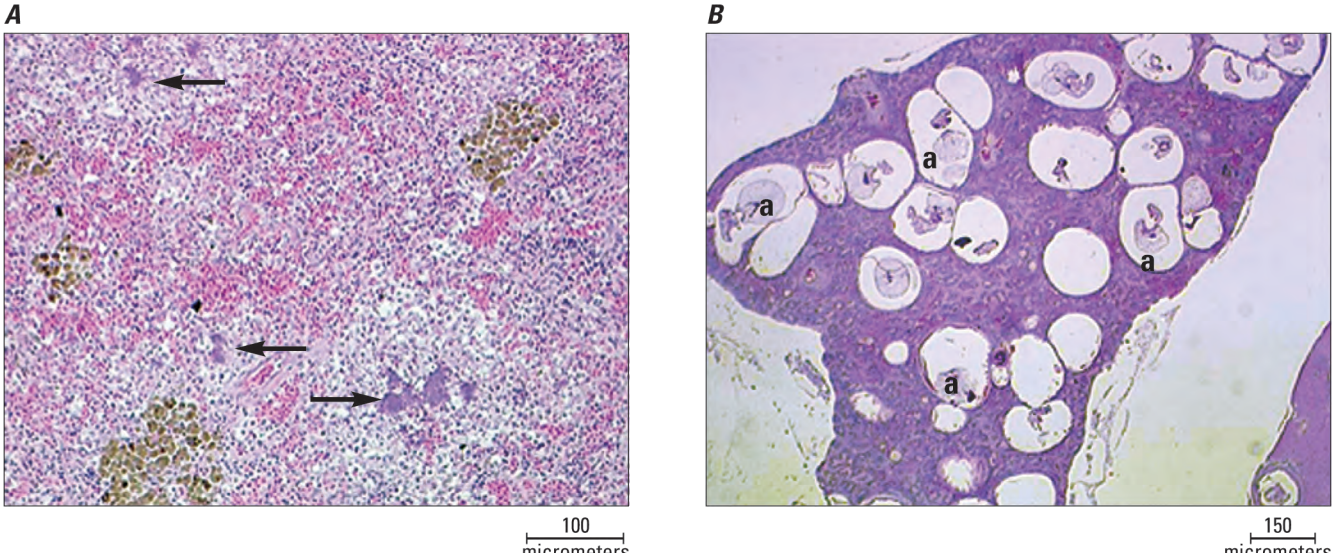

Figure 3. Microscopic observations in tissues of fishes collected from the Chesapeake Bay watershed during mortality events: *(A)* Foci of bacterial microcolonies (indicated with arrows) typical of *Aeromonas salmonicida* systemic infections in the spleen tissue of redbreast sunfish and *(B)* spleen tissue of smallmouth bass with many encysted trematode metacercariae (indicated with an "a") (modified from Blazer and others, 2010).