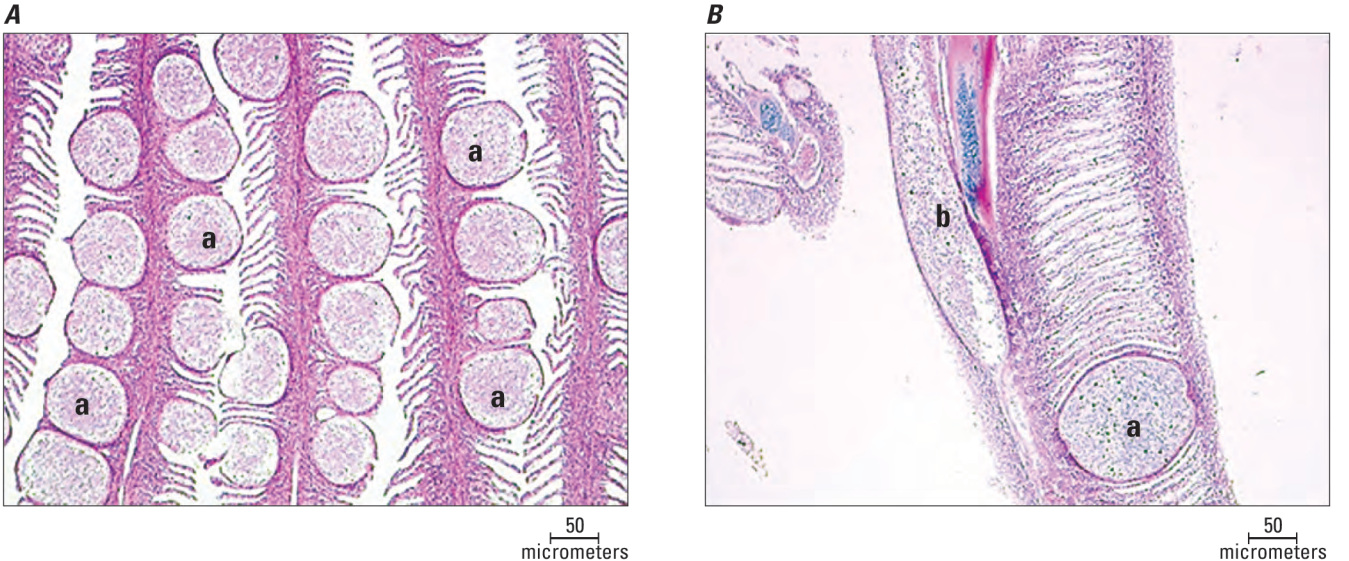

Figure 5. Microscopic observations of gill tissue with myxozoan parasites in smallmouth bass collected from the Chesapeake Bay watershed: *(A)* Heavily infected gill with numerous plasmodia of *Myxobolus branchiarum* (indicated with an "a") and *(B)* mixed infection of *M. branchiarum* (indicated with an "a") and *M. micropterii* (indicated with a "b") (modified from Walsh and others, 2012).